Novel Radiopaque Y-90 Glass Microspheres (Eye90 microspheres™) for Canine Hepatocellular Carcinoma: Correlation of Microsphere Radiopacity with TOF PET Radioactivity and mRECIST Tumor Response Determination

R J Abraham MD FSIR[1], R Davis MD, D Liu, R J Lewandowski MD, FSIR, A C Gordon MD PhD, Z Collins MD FSIR, M Westcott MD FSIR, C Nutting MD FSIR, J Karnia DVM, DACVR, D Y Kim, DVM, PhD, DACVP, M Gregoire, P Eng, A Verma DrPH, MPH, D.Dobrowski, J N Bryan DVM, MS, PhD, DACVIM(Onc)

DALHOUSIE UNIVERSITY

Northwestern University

Lenox Hill Hospital
Northwell Health®

Health Care

THE UNIVERSITY OF KANSAS

SIR 2022 June 11–16 Boston Convention and Exhibition Center

University of Missouri College of Veterinary Medicine

ABK BIOMEDICAL

Disclosures

- ABK Biomedical Incorporated
  - Co-Founder
  - Chief Medical Officer (Employee)
  - Shareholder

The products discussed are investigational and not approved for clinical use in the US

Off Label Use may be discussed during this presentation

Background

Eye90 microspheres™

(Radiopaque Y-90)

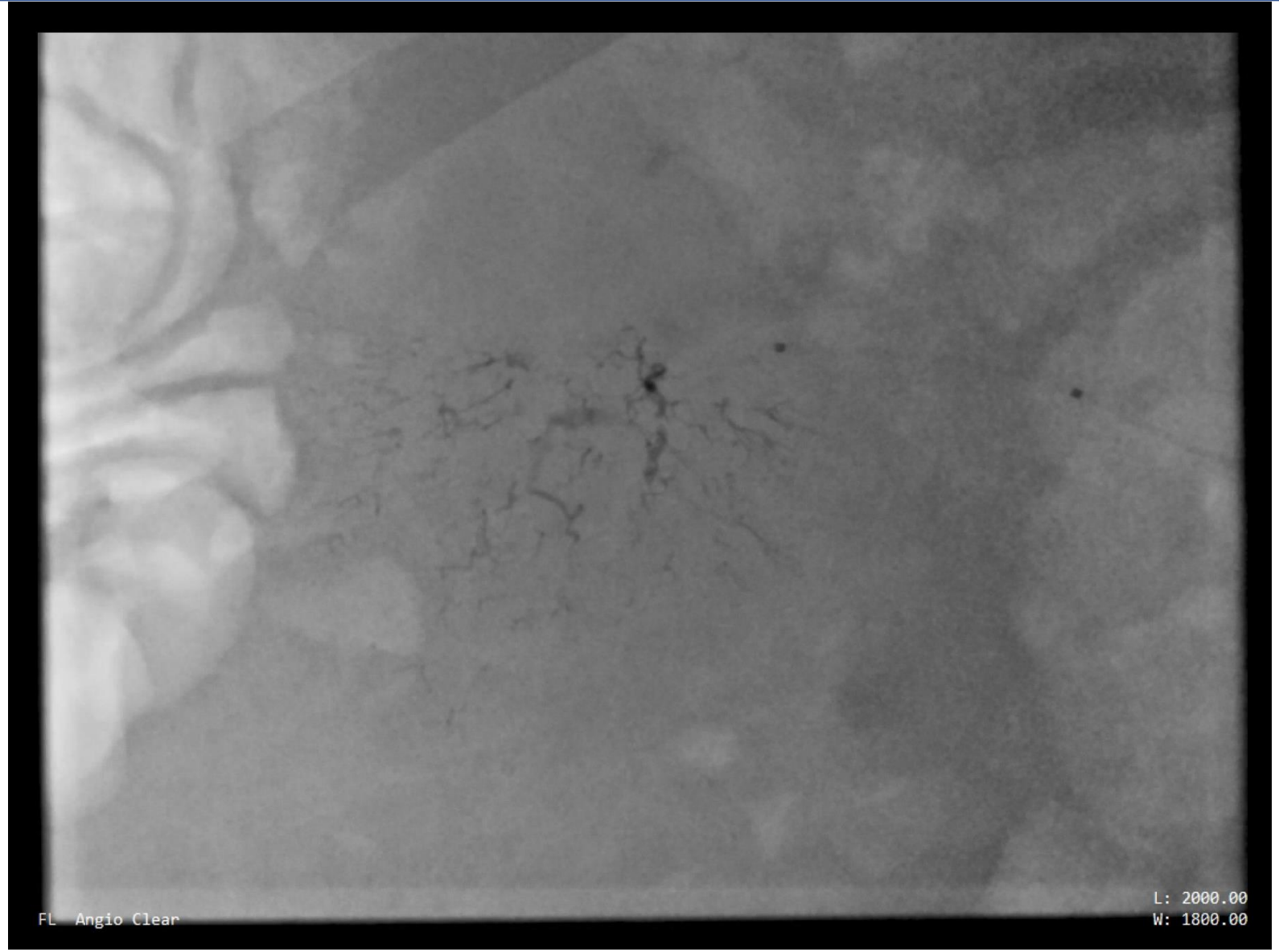

DALHOUSIE UNIVERSITY

The products discussed are investigational and not approved for clinical use in the US

CBCT of Radiopaque ^{90}Y microspheres implanted in Swine Kidney

Images courtesy of ABK Biomedical Inc.

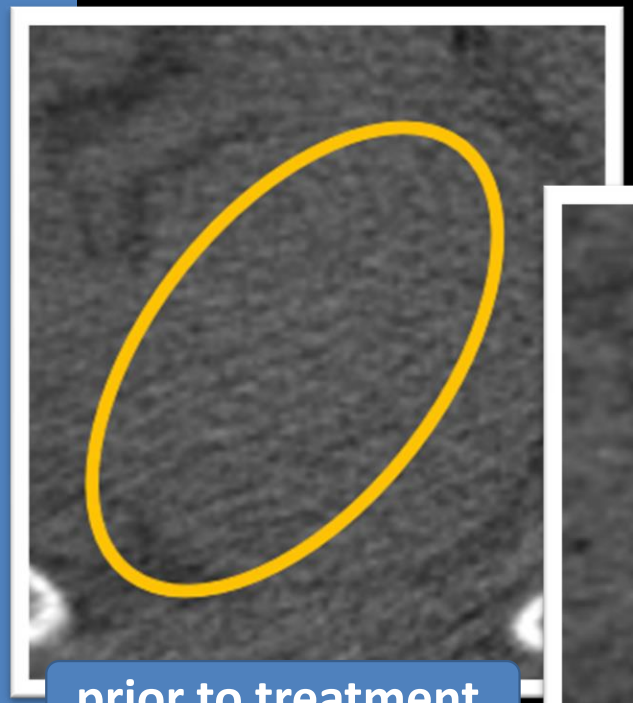

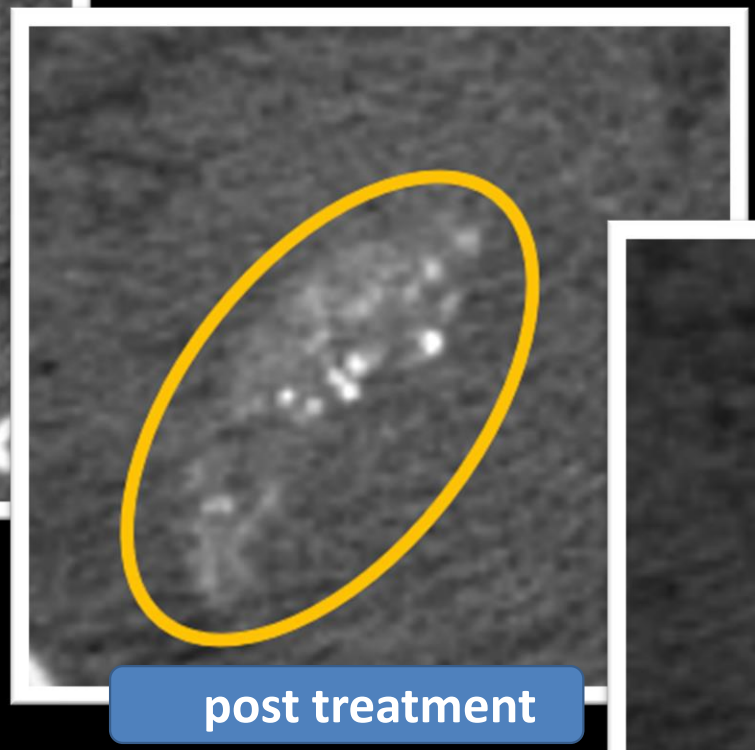

210 HU Threshold

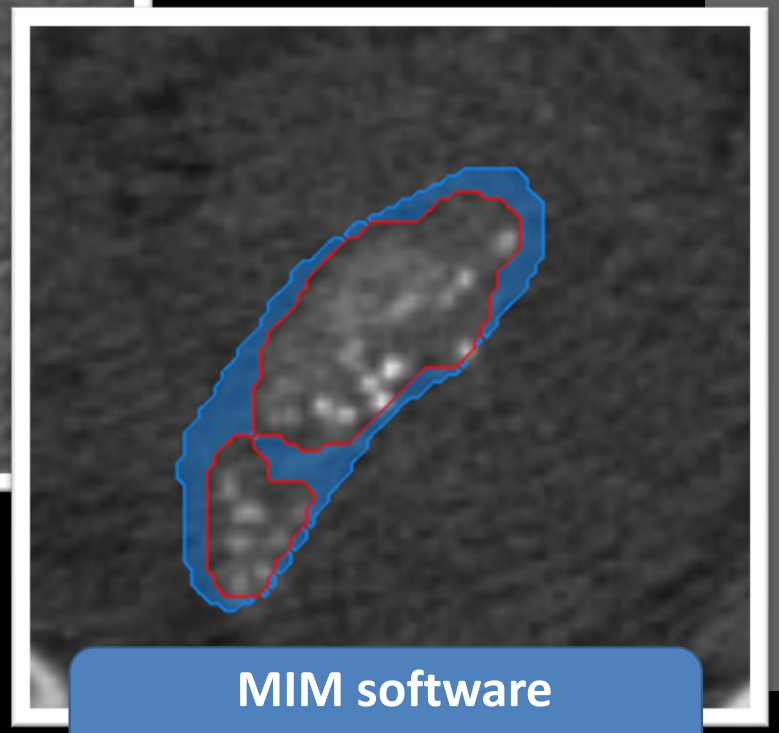

ABK Biomedical products are not approved for clinical use.

DALHOUSIE UNIVERSITY

FIDO TREATS: Companion Dog HCC study

University of Missouri Veterinary Health Center

Disease: Hepatocellular Carcinoma (HCC)
Source: Dog owners volunteering for study participation
Age: ≥ 1 year old
Weight : ≥ 12 kgs
Sex: Male & Female
Number: 6 total (3 Eye90 only & 3 Eye90 plus resection)
Disease: Tumors: up to 3 , 2-12cm total linear length

Study objectives:
(1) Investigate the effectiveness of Eye90 treatment in dogs with HCC
(2) Establish the functional visualization of Eye90 during & post treatment imaging
(3) Evaluate safety through the identification & description of adverse events
(4) Evaluate potential of microsphere radiopacity hindering tumor detection

Veterinary Health Center
University of Missouri

FIDO TREATS:
First in Dog Oncology Trial utilizing Radioembolization Eye90 Advanced Treatment Study

RECRUITING DOGS WITH
LIVER CANCER.
SPONSORED CLINICAL TRIAL

The University of Missouri Veterinary Medical Center is enrolling patients into a clinical trial investigating the use of a novel radioembolization procedure in dogs. All dogs will receive radioembolization and a subset will be evaluated for subsequent resection.

PARTICIPATION:

- Pet owner must be willing to transport their dog to and from the treatment center in Columbia, MO
- A full screening will be performed prior to enrollment
- Suitable patients will receive one radioembolization treatment
- Participation will require a total of up to 5-visits over 6-months

STUDY BENEFITS FOR PARTICIPANTS

- Radioembolization and surgical resection (if eligible)
- Follow-up physical exams and CT imaging at 3- and 6- months
- Contribute to development of an important cancer therapy

BRIEF INCLUSION CRITERIA – All participants must meet the following criteria:

- Be at least 1 year old and weigh at least 12kg (26.4lb)
- Be diagnosed with pathology confirmed hepatocellular cancer
- Have at least one tumor greater than 3cm diameter but no more than a total of 3 tumors
- Have a life expectancy of at least 3 months without treatment
- Have received no prior anti-cancer therapy for this liver tumor
- Have no other diseases or behavioral conditions that would interfere with study conduct.

For more information on this study please contact zellmerd@missouri.edu or visit our trial page

3/19/21 v4

University of Missouri College of Veterinary Medicine

Purpose

- To evaluate tumor response after novel radiopaque Y-90 radioembolic microspheres administration in a Canine Hepatocellular Carcinoma (HCC) model.

Materials and Methods

- Institutional Animal Care and Use Committee Approval
- 8-year-old 31.5 kg male Labradoodle
- 6 cm segment 4b HCC tumor
- Underwent 4 Phase MDCT
- Hepatic mapping angiography
- 99mTcMAA planar gamma imaging
- Radioembolization with novel radiopaque glass Y-90 microspheres
- Post Y-90 TOF PET/CT
- MDCT (mRECIST response) @ 6-weeks
- Left Lobectomy and Histopathology @ 6-weeks

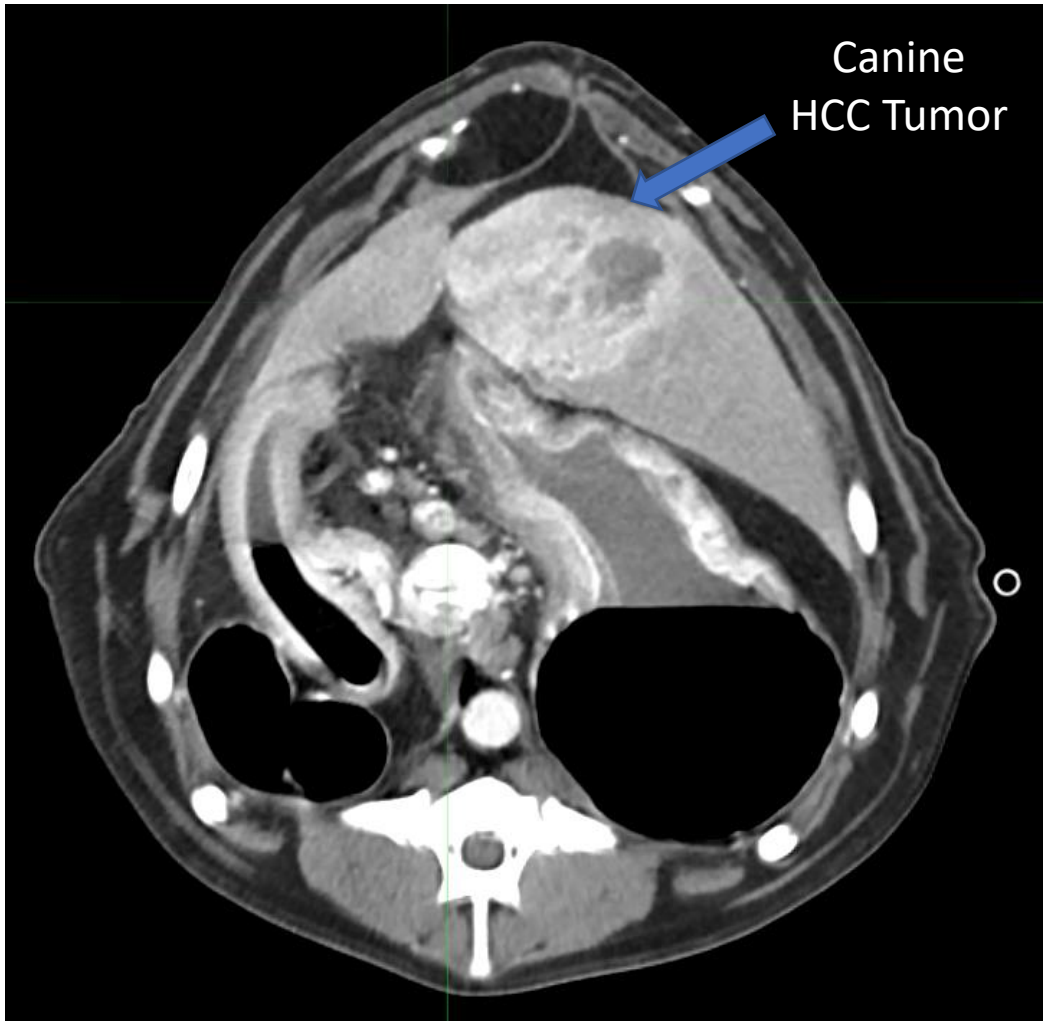

DALHOUSIE UNIVERSITY

Materials and Methods

- MDCT

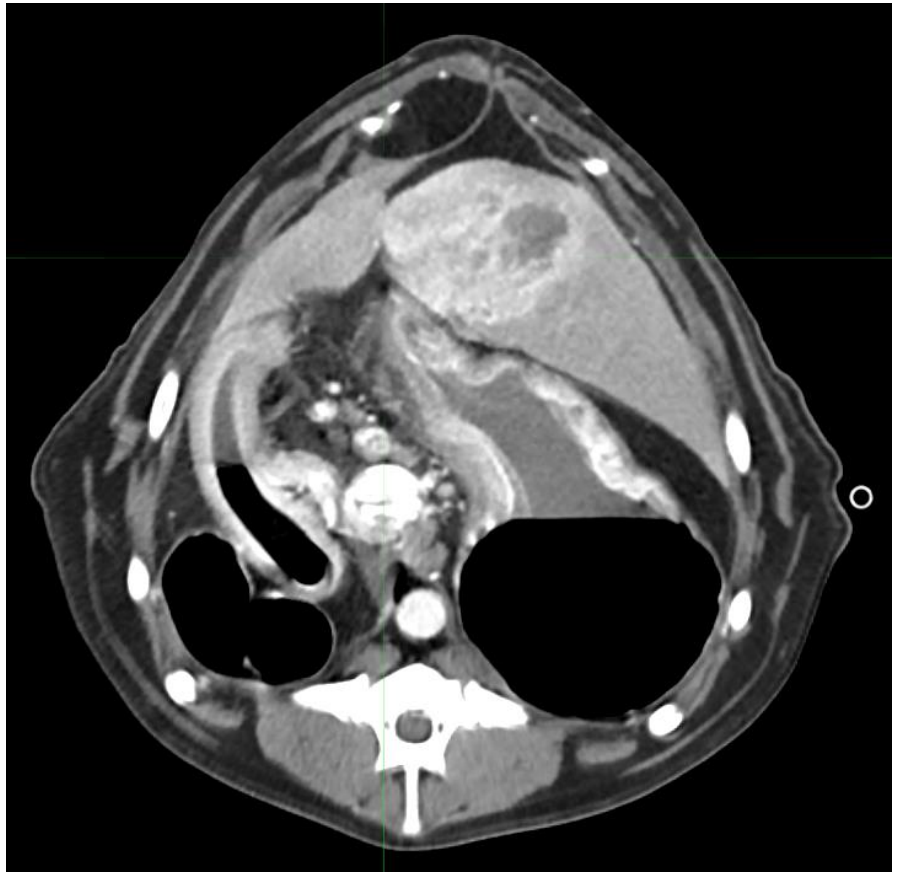

The products discussed are investigational and not approved for clinical use in the US

Materials and Methods

- Hepatic mapping angiography

CINE

DSA

The products discussed are investigational and not approved for clinical use in the US

Materials and Methods

- ^{99m}TcMAA planar gamma imaging to obtain LSF and TNR



Left and Right Lateral Decubitus Geometric Mean

The products discussed are investigational and not approved for clinical use in the US

Materials and Methods

- Radioembolization with novel radiopaque glass Y-90 microspheres (Eye90 microspheres™)

Unit Dose: 1.2 GBq & 120 mg

2.4 Fr 0.021” ID Microcatheter

Residual ~ 6%

Activity Delivered: 1.15 GBq (31.07 mCi)

The products discussed are investigational and not approved for clinical use in the US

Results

Parameters:

Whole Liver Volume (V_{WL}) = 1257 mL

Perfused Volume (V_{Perf}) = 412 mL

Tumor Volume (V_{tumor}) = 137 mL

Lung Shunt Fraction (LSF) = 1.6%

TNR 1.7

The products discussed are investigational and not approved for clinical use in the US

Results

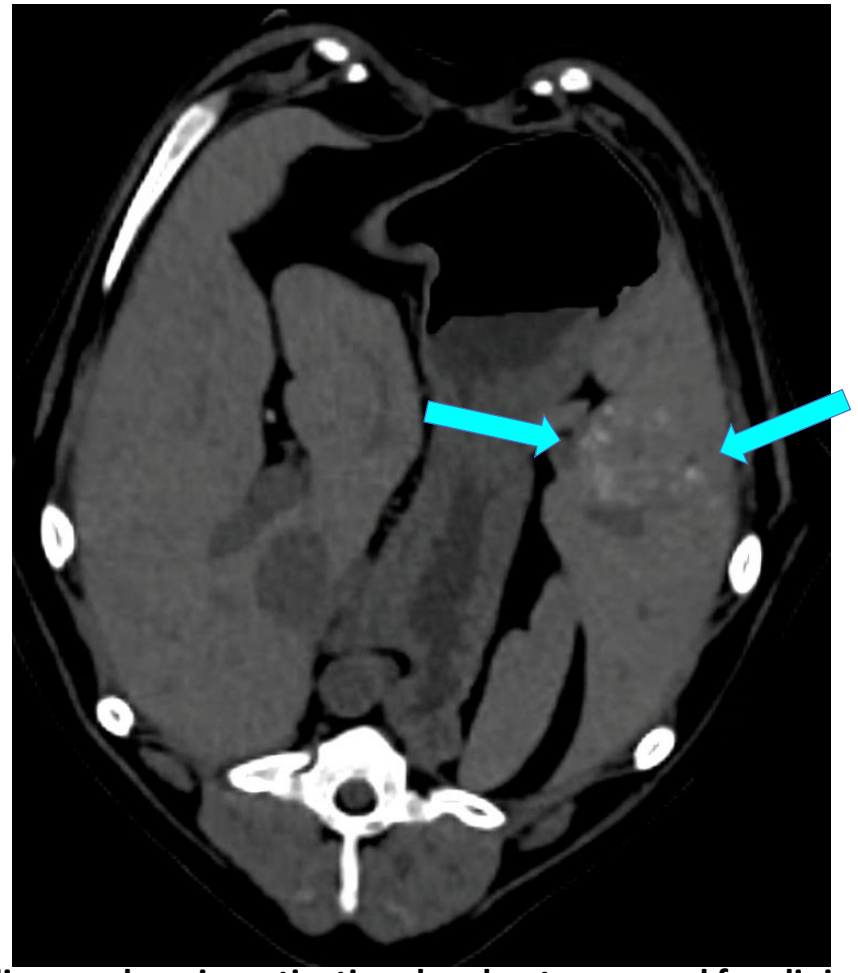

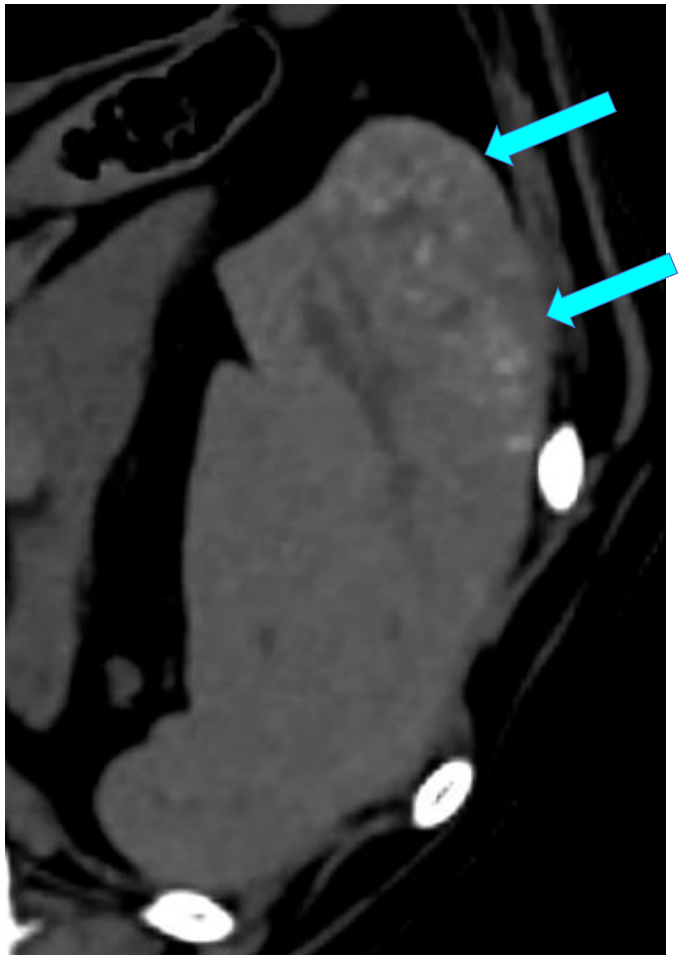

The products discussed are investigational and not approved for clinical use in the US

Results

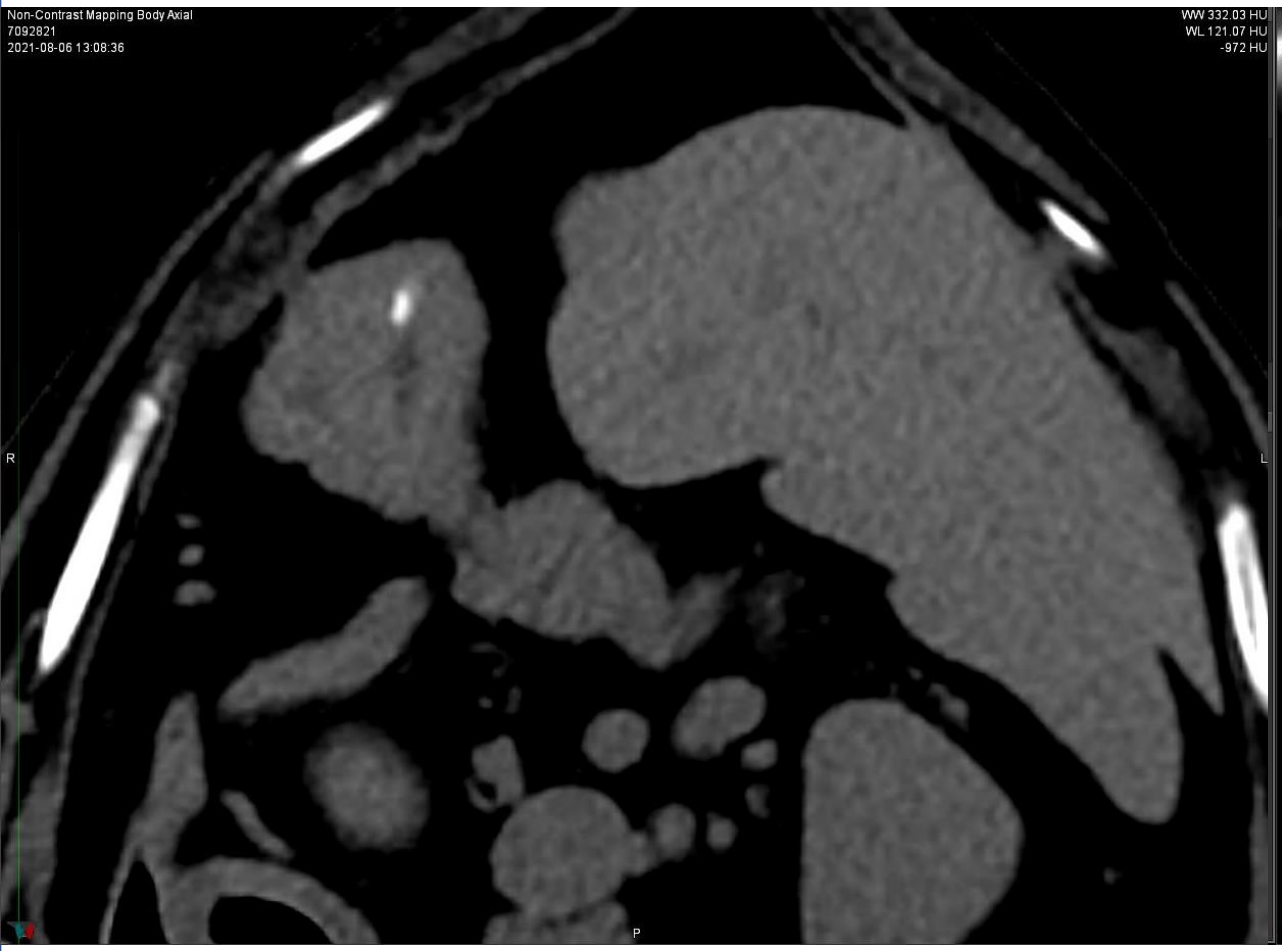

Baseline Unenhanced CT

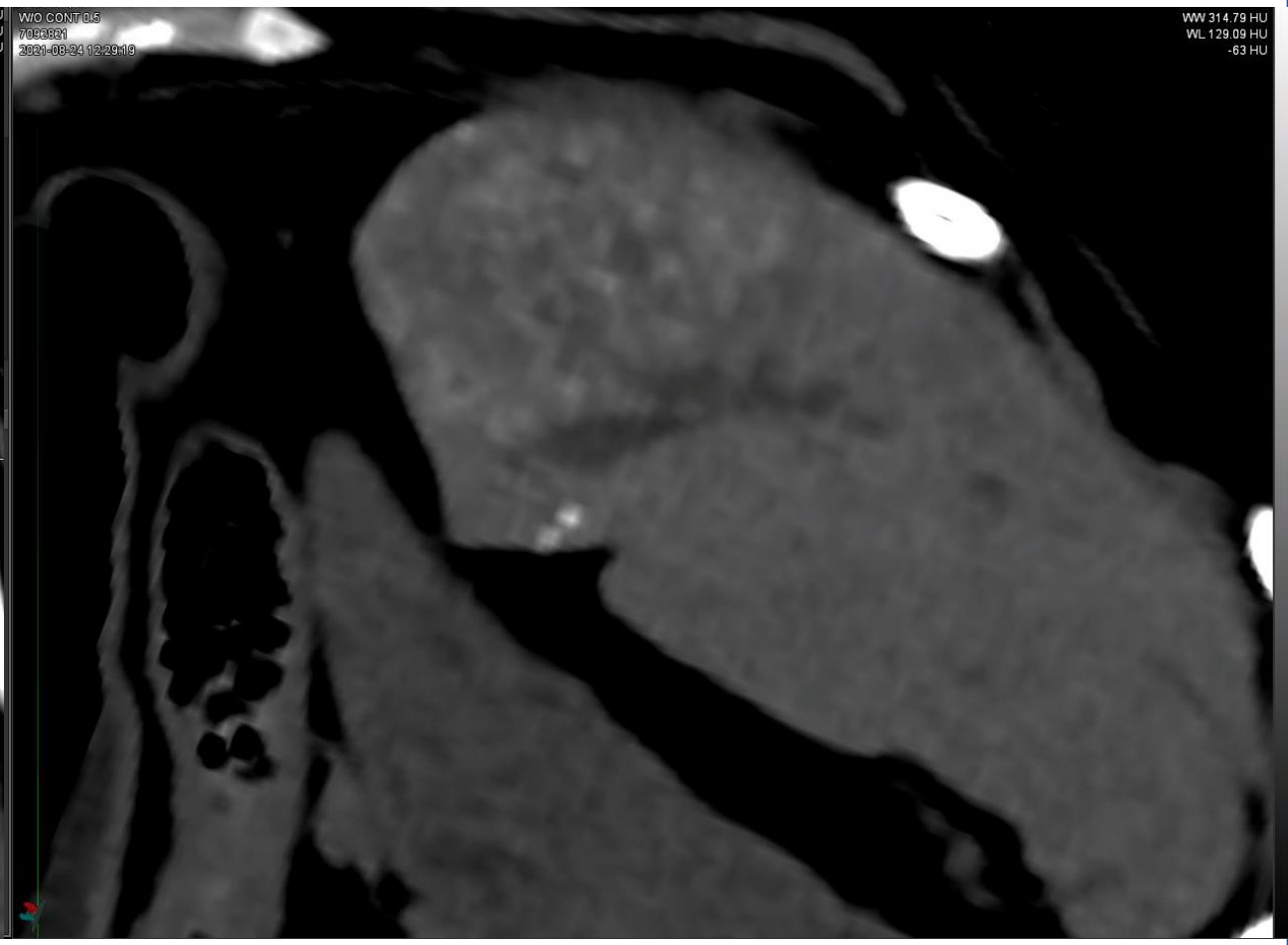

Post Eye90 Unenhanced CT

The products discussed are investigational and not approved for clinical use in the US

Results

Post therapy CT demonstrated Eye90 radiopacity distribution throughout tumor
Indicating excellent targeting with no attenuation artifact or distortion of CT imaging

Conventional CT

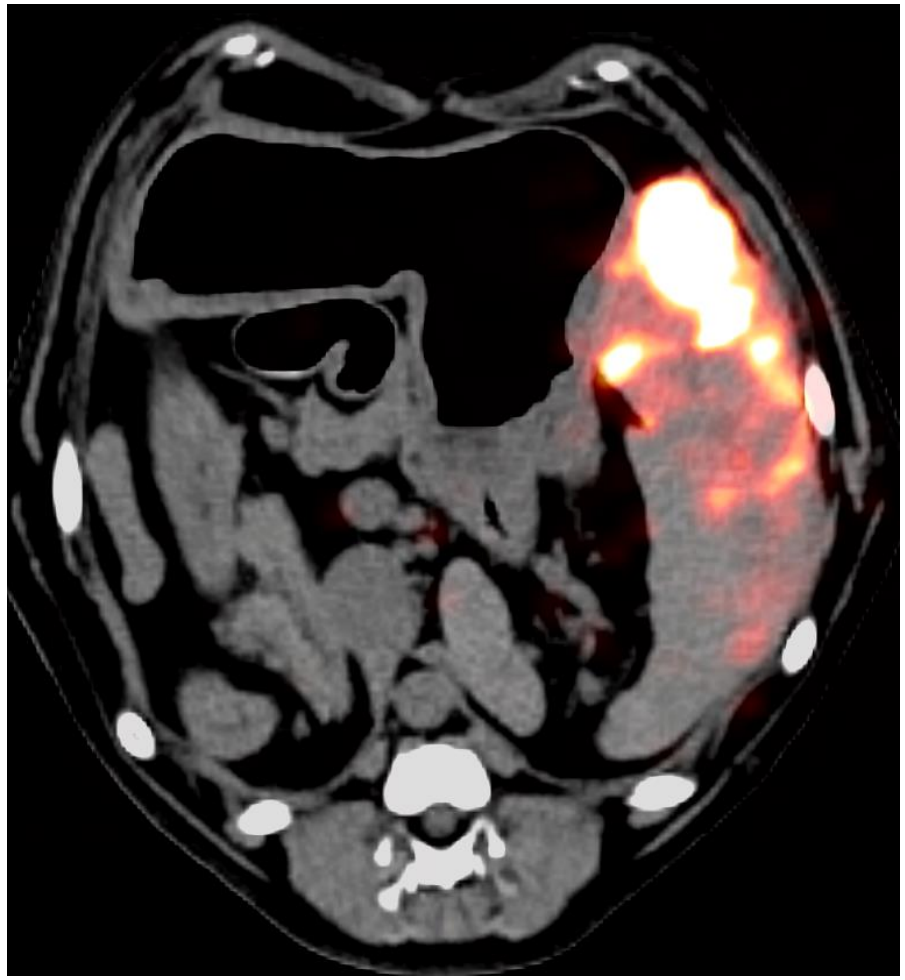

Fused PET/CT

The products discussed are investigational and not approved for clinical use in the US

Results

Post Eye90 PET/CT Absorbed Dose Values:

Perfused Volume Dose (D_{perf}) = 148 Gy;

Tumor Dose (D_{Tumor}) = 316 Gy

Perfused Normal Liver Dose (D_{PNL}) = 30 Gy

The products discussed are investigational and not approved for clinical use in the US

• Post Eye90 Dosimetry Report

Y90 Post-Operative Dosimetry Report

MIM-Generated DVHs

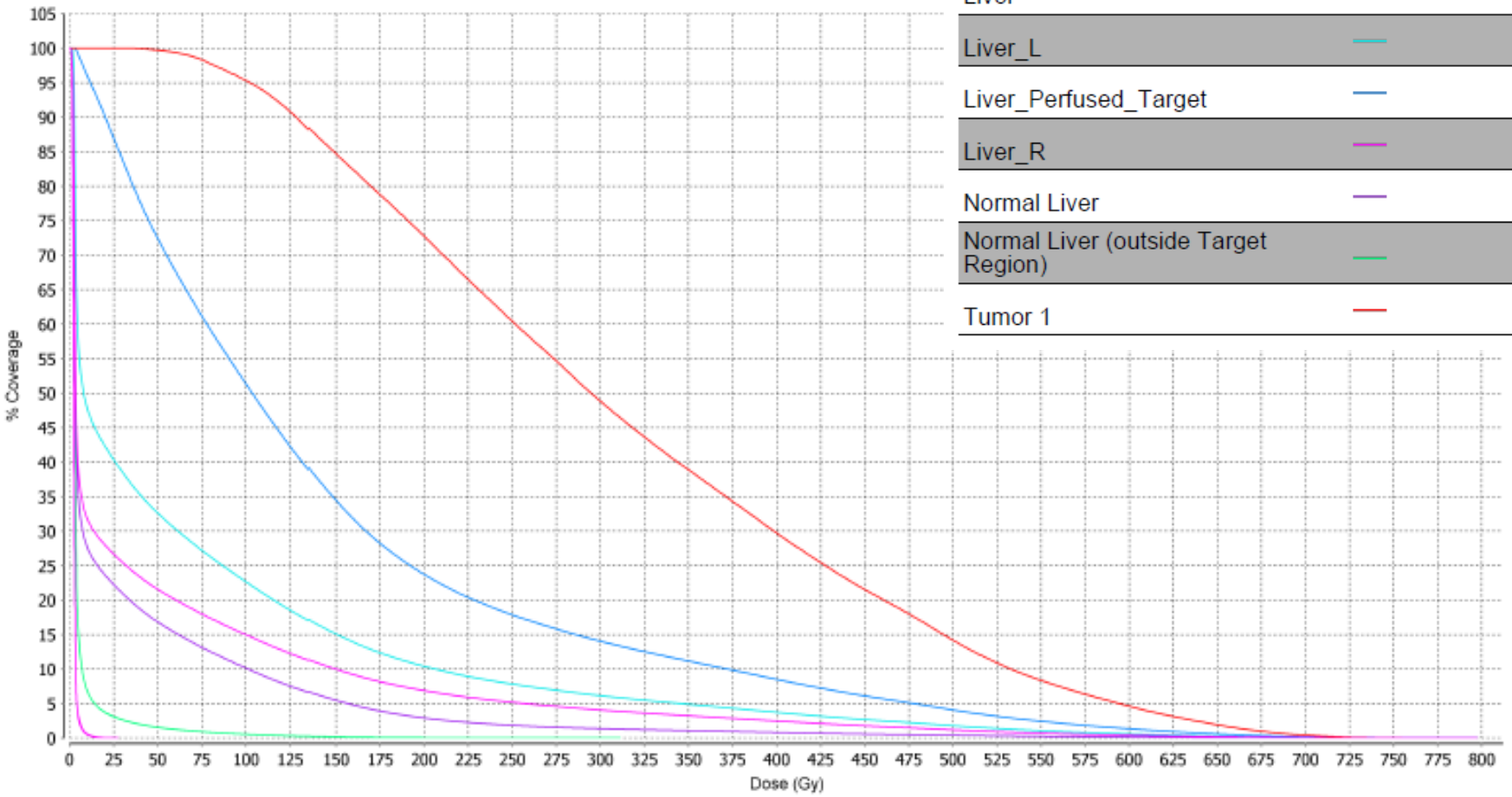

Contour	Line Style	Max Dose	Min Dose	Mean Dose	SD
	D1	D1	D1	D1	D1
Liver		811.68	0.54	46.27	101.21
Liver_L		811.68	1.04	68.63	118.37
Liver_Perfused_Target		811.68	2.78	148.46	143.18
Liver_R		28.14	0.54	2.61	1.24
Normal Liver		811.68	0.54	29.99	69.20
Normal Liver (outside Target Region)		311.15	0.54	5.52	13.10
Tumor 1		760.85	30.00	315.78	153.19

Mean Dose to Tumor
316 Gy

The products discussed are investigational and not approved for clinical use in the US

Results

- Excellent recovery – No ill effects
- Discharged three days after Eye90
- Repeat CT in 6 weeks
- Surgical resection at 6 weeks
- Pathology Assessment
  - Assess for tumor viability
  - Assess for tumor necrosis

The products discussed are investigational and not approved for clinical use in the US

Baseline CT versus CT 6 Weeks Post Eye90

Baseline CT Late Arterial Phase

6 Week CT Late Arterial Phase

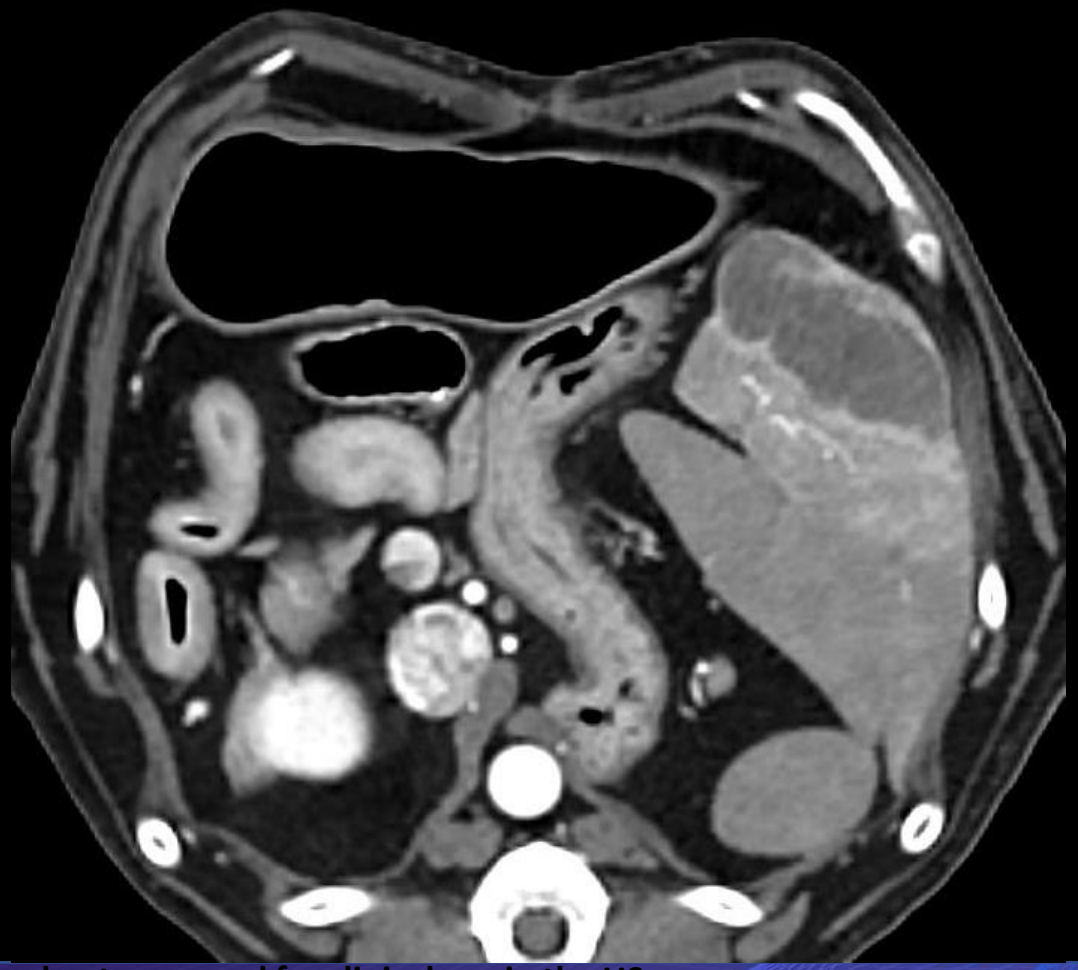

The products discussed are investigational and not approved for clinical use in the US

mRECIST Response at 6 weeks = 74%

Results

6-Week Left Lobectomy and Histopathology

Pathologic Response at 6 weeks = 80% necrosis

The products discussed are investigational and not approved for clinical use in the US

Conclusions

Radioembolization of Canine HCC with radiopaque Eye90 microspheres™ demonstrated significant anti-tumor response 6 weeks after therapy at D_{Tumor} of 316 Gy.

Baseline CT Late Arterial Phase Demonstrating Tumor Enhancement

Eye90 Radiopacity on Unenhanced CT Scan

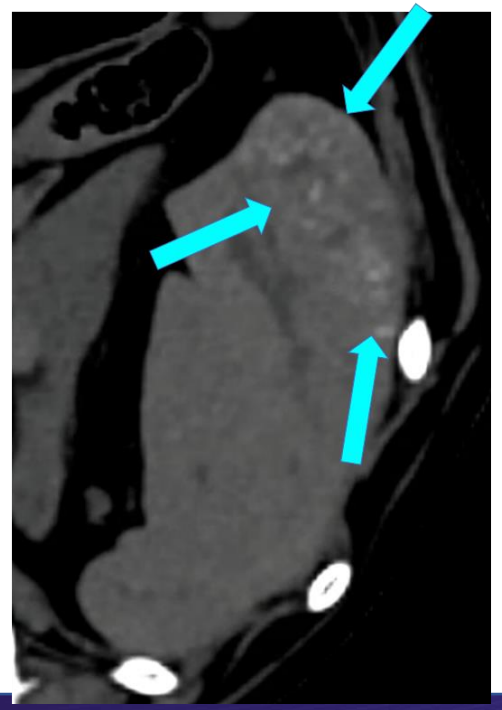

6 Week CT Late Arterial Phase Demonstrating Necrosis of Tumor

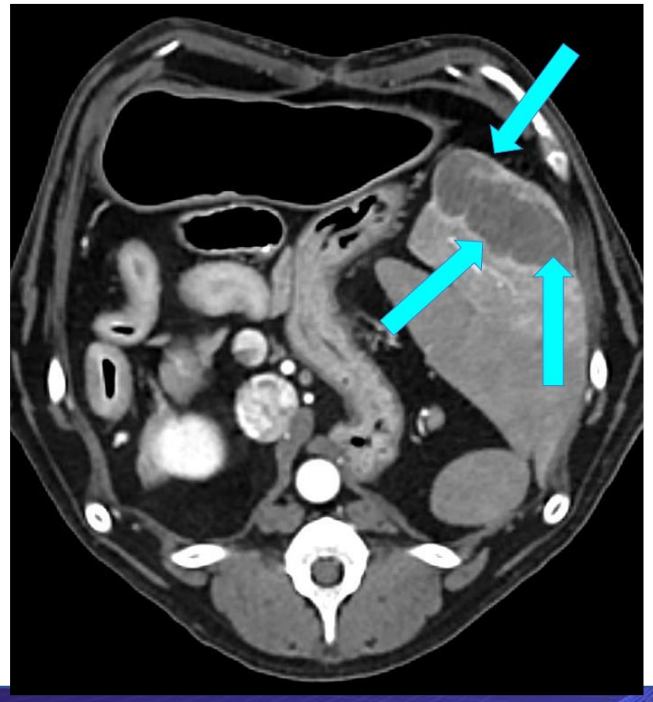

The products discussed are investigational and not approved for clinical use in the US

Clinical Impact

This case shows Eye90 microspheres™ provided good tumor response with the ability to assess tumor targeting and coverage on CT with inherent radiopacity correlating well with PET based radioactivity.

If radiopacity can be correlated with MS quantity, minimum radiopacity tumor absorbed dose thresholds may be possible.

Continued clinical research is ongoing with FIDO Treats and First in Human Trial in New Zealand

The products discussed are investigational and not approved for clinical use in the US

Contact Information

Bob Abraham MD, FSIR, FCIRSE, FRCPC
Division of Interventional Radiology
Department of Radiology
Dalhousie University
QEII Health Sciences Center
Halifax, NS, Canada
robert.abraham@dal.ca
www.linkedin.com/in/bob-abraham-interventional-radiologist-dalhousie-university

https://peakvisor.com/img/news/Nova-Scotia.jpg